



PATIENT

Storm Borden

SPECIES

Feline

BREED

DSH

SEX

Female Spayed

AGE

8 years

WEIGHT

9lbs

INTERPRETED BY

Maggie Machen Lamy,
 DVM DACVIM
 (Cardiology)

IMAGING PERFORMED BY

Kelly Reschny, RVT

HOSPITAL NAME

Lakeshore Woods
 Animal Hospital

REFERRING VET

Dr. Masoud

INVOICE

46382

DATE

1/12/26

PRESENTING CLINICAL SIGNS

History: Grade 4-5/6 heart murmur.

ECHOCARDIOGRAM FINDINGS

2D, m-mode, color flow and doppler imaging is available. The left ventricular wall is normal in dimension. There is a mildly hyperechoic endocardium consistent with age-related fibrosis. Mild remodeling. The papillary muscles are hyperechoic yet normal in size. The left atrium is normal in size. The right atrium is normal in size. The right ventricle appears normal. The mitral valve is normal in structure and mobility. No MR or SAM identified. The tricuspid valve appears normal in structure and mobility. No TR. Blood flow through both the LVOT and RVOT are normal in velocity. No AI/PI seen. No effusions. No obvious cardiac tumors.

CARDIAC CHART

FELINE CARDIAC PARAMETERS	BODY WEIGHT (kg)	HR (BPM)	IVSd (cm) (Moise, Pipers)	LVIDd (cm) (Moise, Pipers)	LVWd (cm) (Moise, Pipers)	FS (%)	EF (%)
NORMAL PARAMETER	-----	150-240	0.35-0.55	<2 (mean 1.5)	3.5-0.55	35-67	80-100
PATIENT	4.1	130	0.45	1.0	0.44	60	90
FELINE CARDIAC PARAMETERS	LA/AO (Boon)	LA/AO HEART BASE (Swe) (Abbott)	LA 2D short axis Base view (cm) (Abbott)		LVOT VEL (m/s)	RVOT VEL (m/s)	E max (m/s)
NORMAL	<1.5	<1.3	<1.2		<1.6	<1.3	<0.9
PATIENT	1.2	1.1	1.0		1.0	1.1	NM
*Note: All measurements based upon multi-modal images and methods. An average value is reported. Adapted from June Boon, Veterinary Echocardiography, 1998 Abbott J & MacLean H JVIM 2006;20: 111-119, Moise et al. Am J Vet Res 47:1476, 1986. Pipers et al. Am J Vet Res 40:882, 1979.							

INTERPRETATION OF THE FINDINGS & FURTHER RECOMMENDATIONS

Overtly normal cardiac structure and function. Mild fibrosis of the left ventricular wall is noted, which is likely a normal age-related variant. No significant valve leaks are noted, and flow through the great vessels is normal in velocity. No definitive cause for the murmur is identified in this study, making it likely physiologic in origin (i.e. secondary to tachycardia, volume changes, etc.). That said, a grade V murmur without an obvious origin is somewhat concerning that an abnormality may have been missed. If the intensity is consistent and a thrill confirmed, referral should be considered.

Given these findings and a normal LA dimension, no medications are indicated. Prognosis is open.

No cardiac contraindication for general anesthesia. Risk for complication with steroid or fluid use typically follows LA dilation, which in this case is low. That said, any cat can experience acute intolerance and monitoring for this phenomenon is always advised (a change in RR/RE, particularly during the initiation phase).

Monitor at home for signs of cardiac compromise, including respiratory changes and/or signs of a blood clot event (paralysis, neurologic changes).



PATIENT

Storm Borden

Recommend recheck echocardiogram in 1 year to assess for any progressive issues or development of disease the pre-existing murmur may mask.

IMAGES

SPECIES

Feline

BREED

DSH

SEX

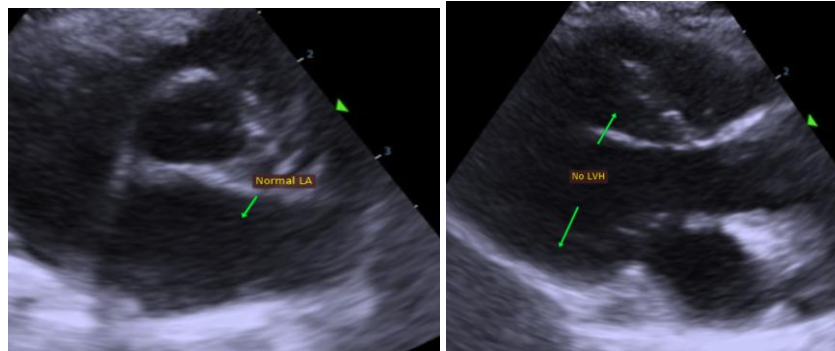
Female Spayed

AGE

8 years

WEIGHT

9lbs



The information and recommendations provided are based on the images presented by the referring veterinarian. No evaluation can be communicated regarding pathology that was not visible in the image/video clips provided.

Thank you for this referral. This report was generated using transcription software, and minor dictation errors may be present. If the clinical or image interpretation does not parallel your findings or if I can be of any further assistance, please contact me.

INTERPRETED BY

Maggie Machen Lamy,
DVM DACVIM
(Cardiology)

Maggie Machen Lamy, DVM
Diplomate of the American College of Veterinary Internal Medicine (Cardiology)
info@sonopath.com

IMAGING PERFORMED BY

Kelly Reschny, RVT

HOSPITAL NAME

Lakeshore Woods
Animal Hospital

REFERRING VET

Dr. Masoud

INVOICE

46382

DATE

1/12/26